PRIMARY OPEN-ANGLE GLAUCOMA

1. Definition and risk factor
2. Theories of glaucomatous damage
3. Optic disc cupping
4. Visual field defects
5. Medical therapy
6. Laser trabeculoplasty
7. Trabeculectomt
   - Indications
   - Technique
   - Filtration blebs
   - Complications

Definition and risk factors

IOP > 21 mmHg

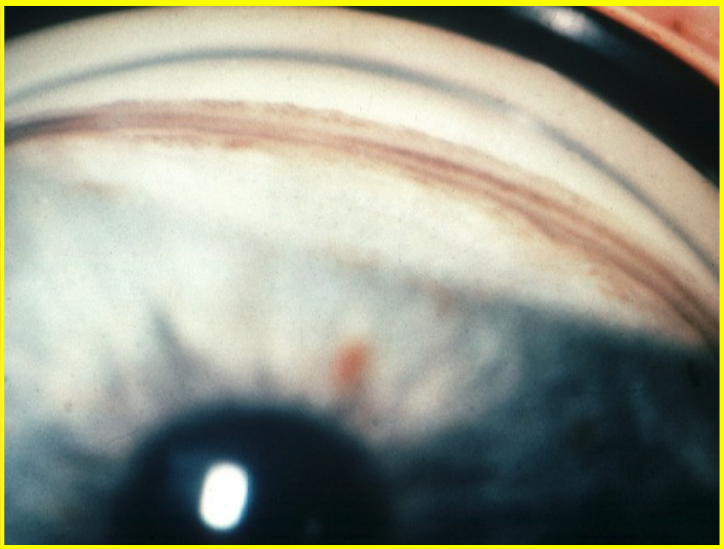

Open angle of normal appearance

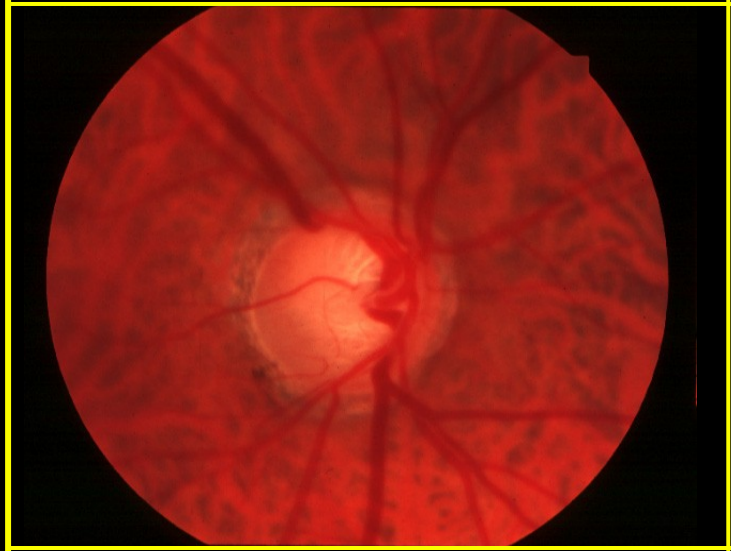

Glaucomatous disc damage

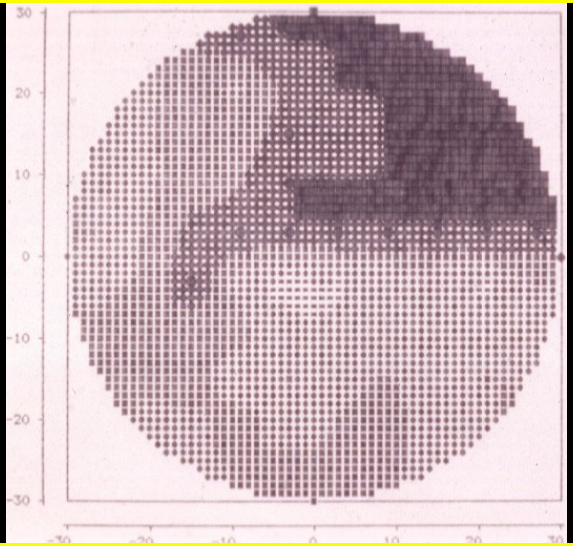

Visual field loss

Risk Factors

1. **Age** - most cases present after age 65 years

2. **Race** - more common, earlier onset and more severe in blacks

3. **Inheritance**
   - Level of IOP, outflow facility and disc size are inherited
   - Risk is increased by x2 if parent has POAG
   - Risk is increased x4 if sibling has POAG

4. **Myopia**

Theories of glaucomatous damage

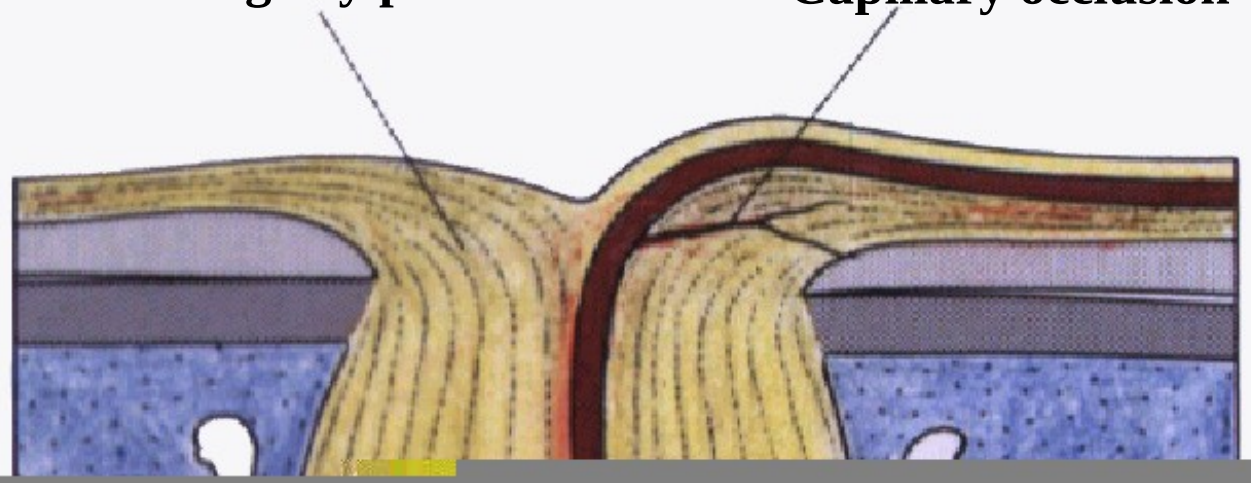

Interference with axoplasmic flow

Concentric excavation

1984

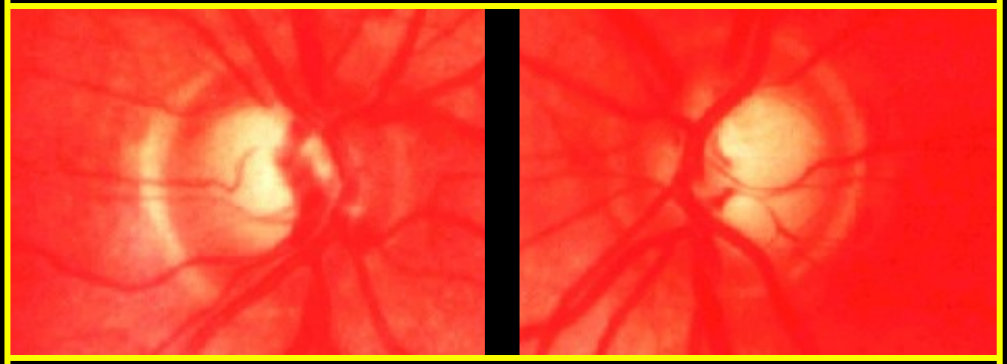

1994

- Diffuse loss of nerve fibres
- Excavation enlarges concentrically
- Initially may be difficult to distinguish from large physiological cup
- Compare with previous record

Localized cupping

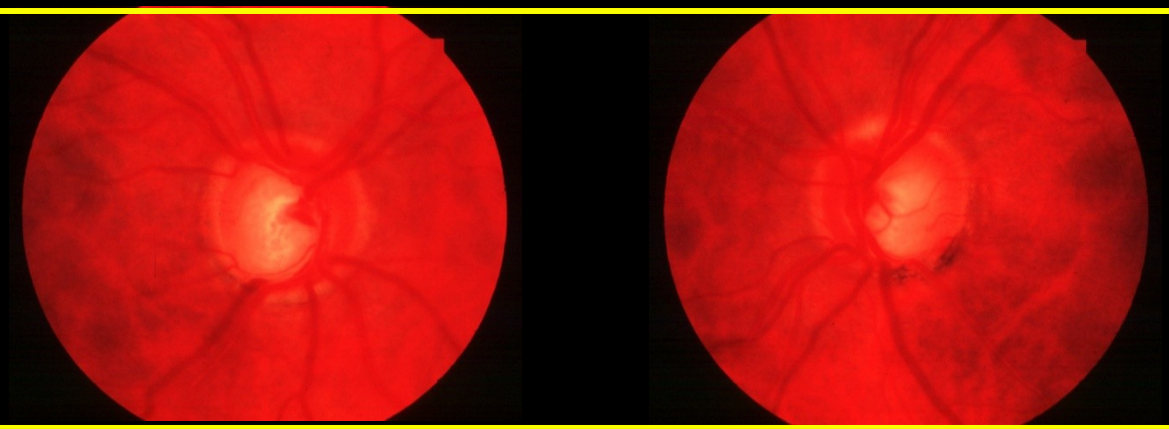

- Focal loss of nerve fibres
- Notching at superior or more commonly inferior poles
- Excavation becomes vertically oval
- Double angulation of blood vessels (‘bayoneting sign’)

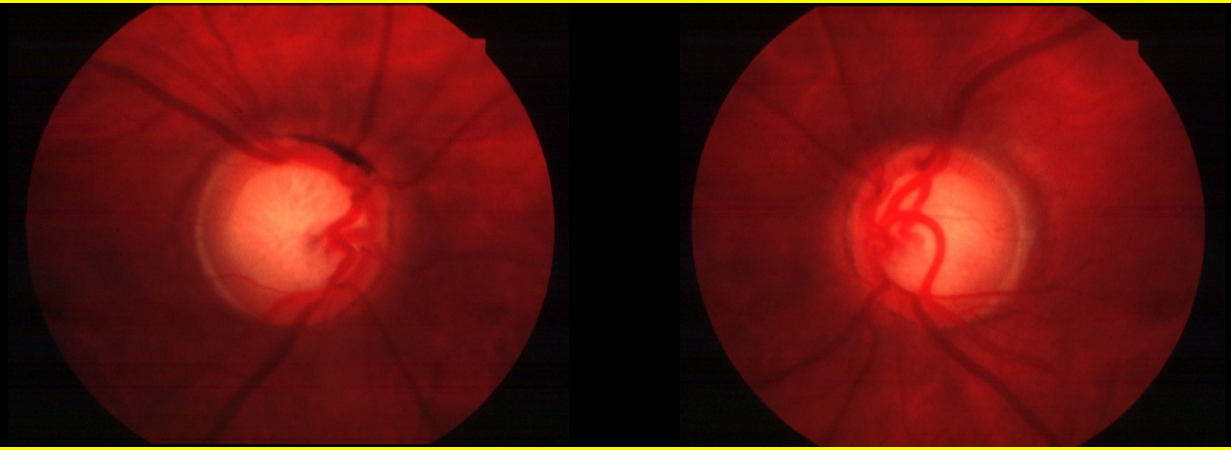

- Diffuse loss of nerve fibre
- Excavation enlarges concentric cupping
- Nasal displacement of central blood vessels

Progression of nerve fibre damage

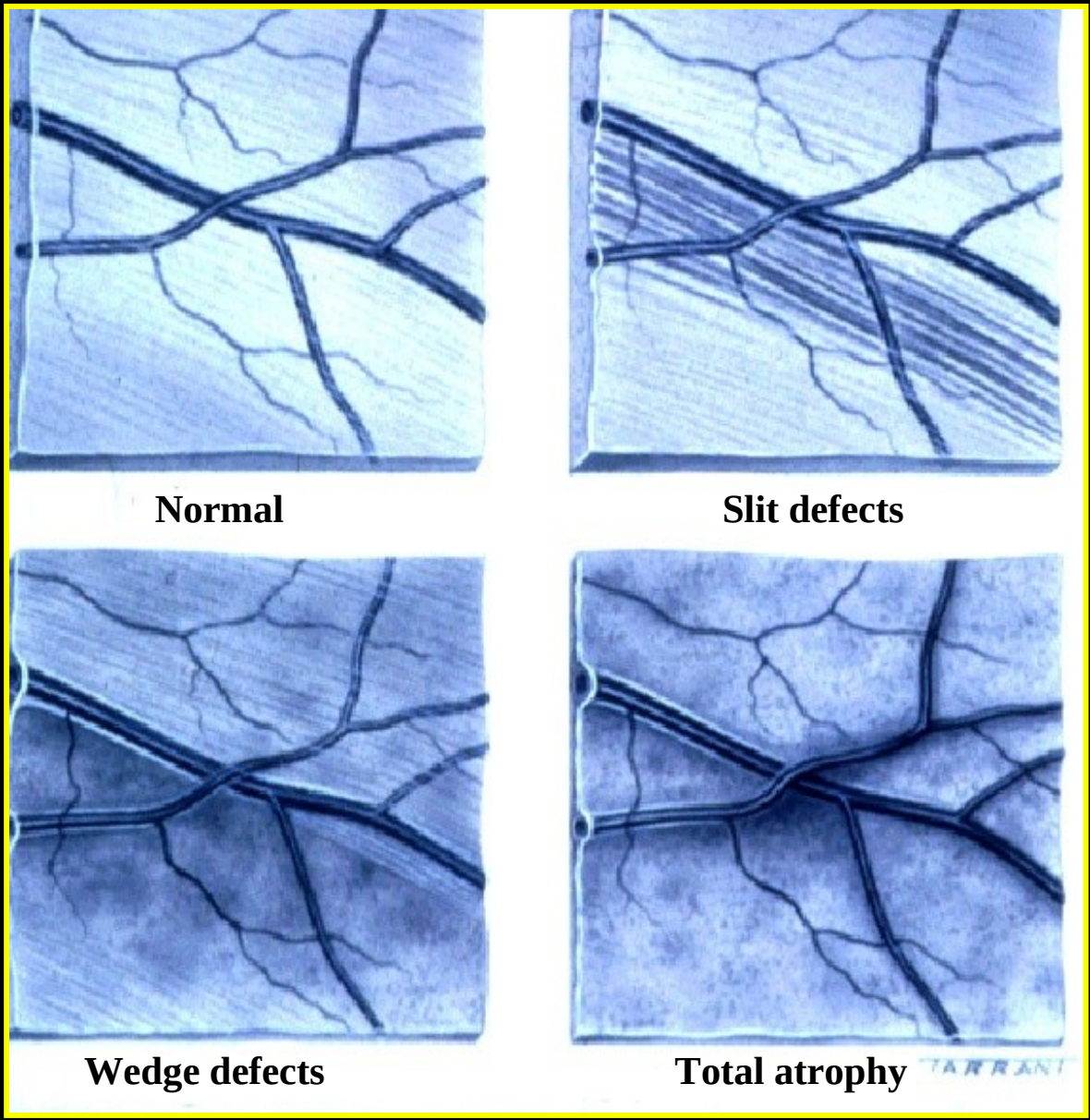

End-stage damage

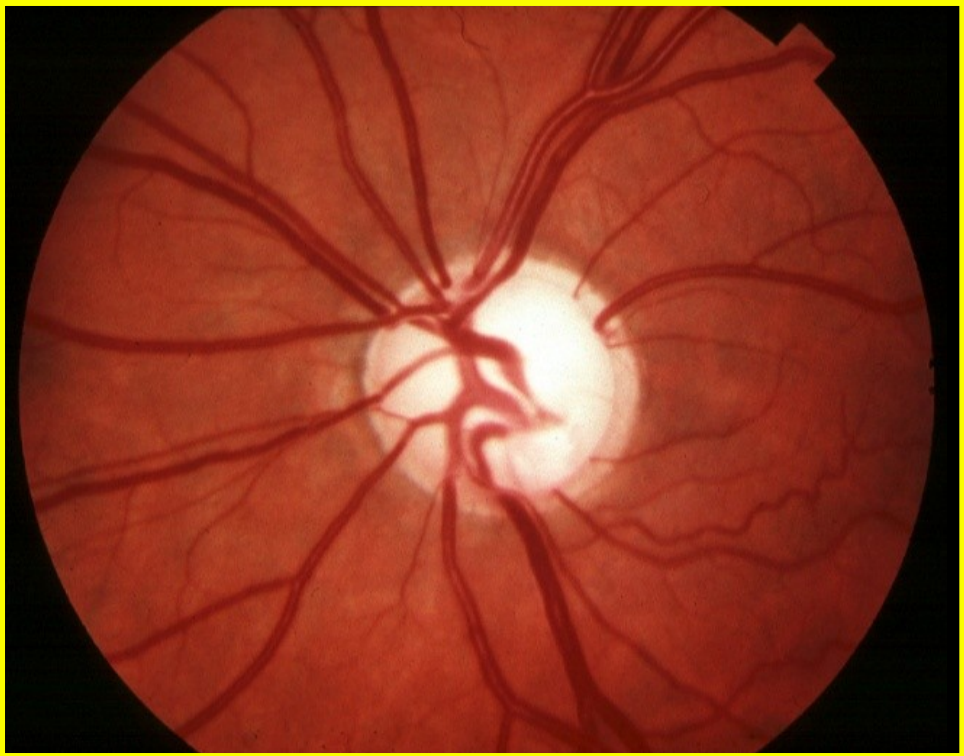

- All neural disc tissue is destroyed
- Disc is white and deeply excavated

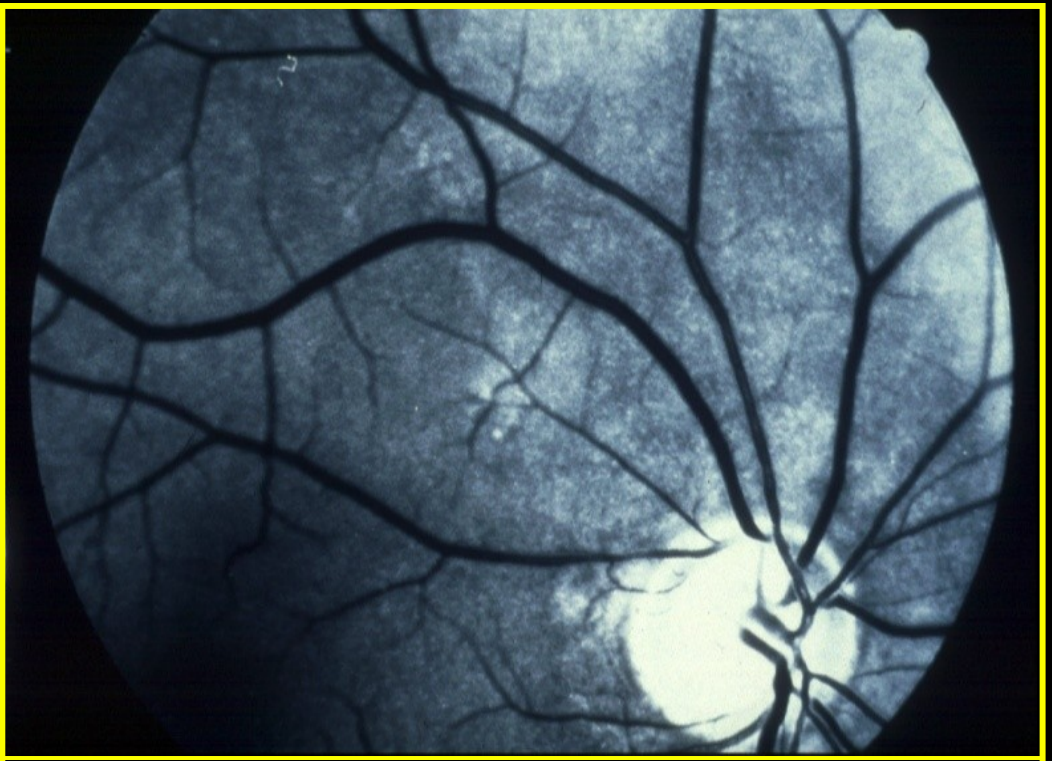

- Atrophy of all retinal nerve fibres
- Striations are absent
- Blood vessels appear dark and sharply defined

Progression of glaucomatous cupping

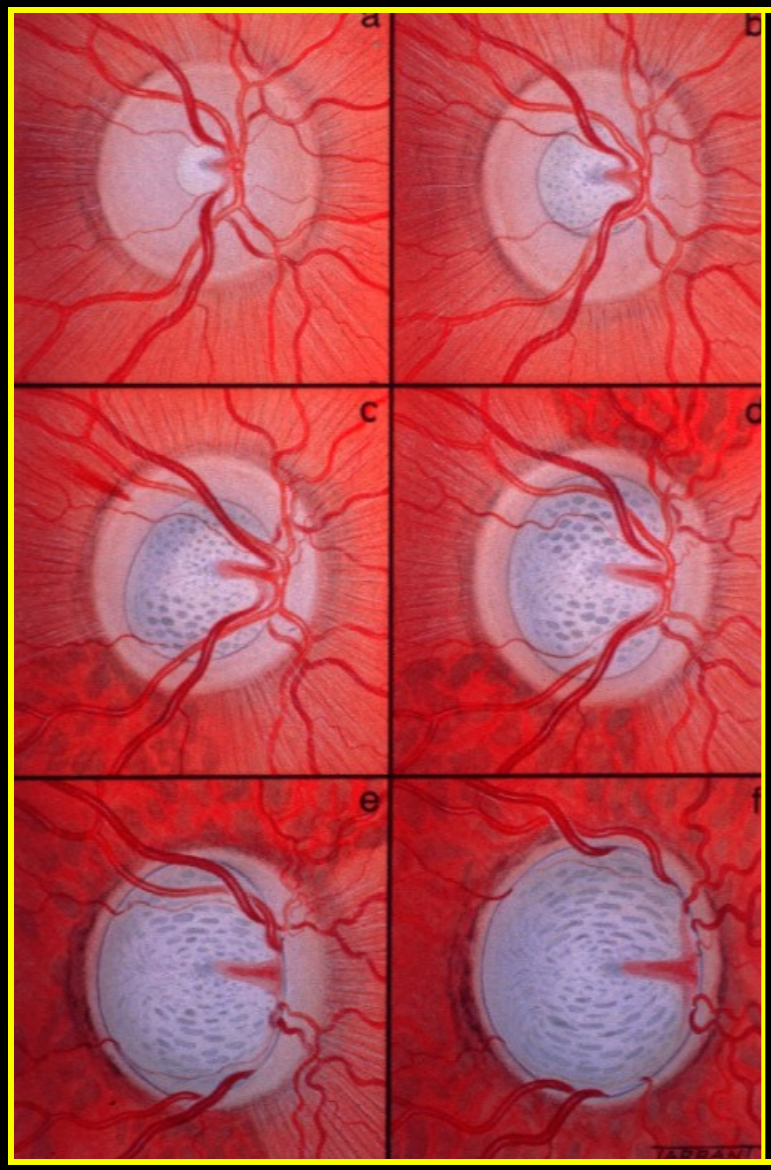

a. Normal (c:d ratio 0.2)

b. Concentric enlargement (c:d ratio 0.5)

c. Inferior expansion with retinal nerve fibre loss

d. Superior expansion with retinal nerve fibre loss

e. Advanced cupping with nasal displacement of vessels

f. Total cupping with loss of all retinal nerve fibres

Early visual field defects

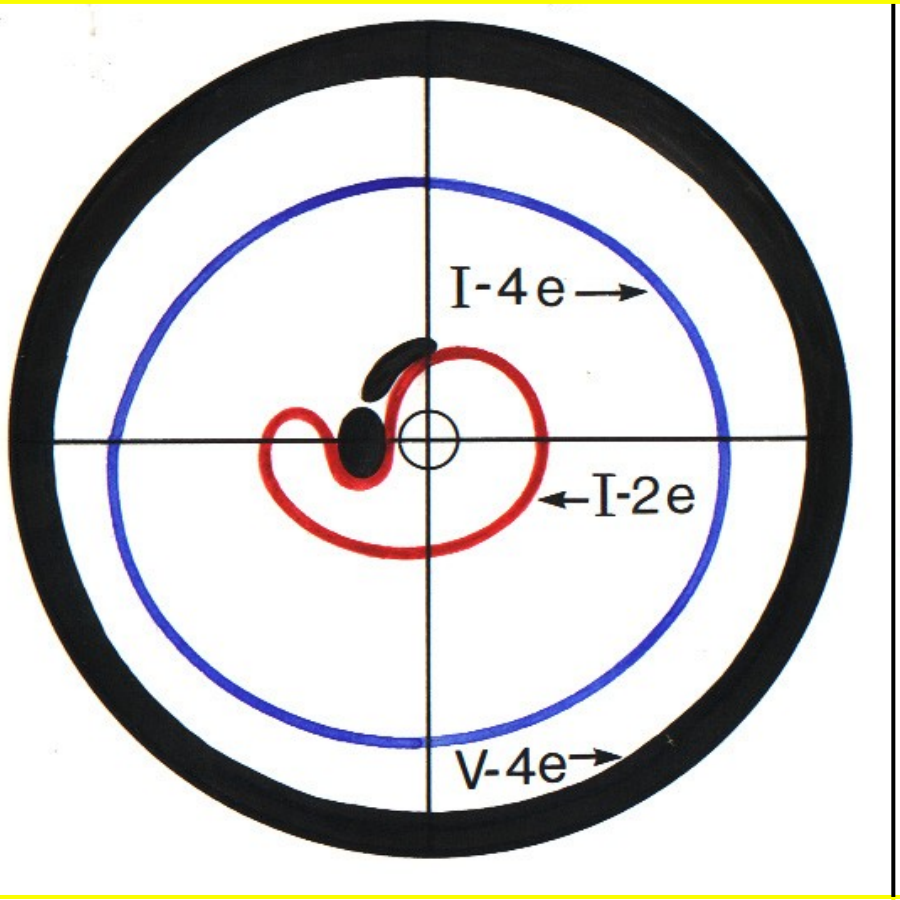

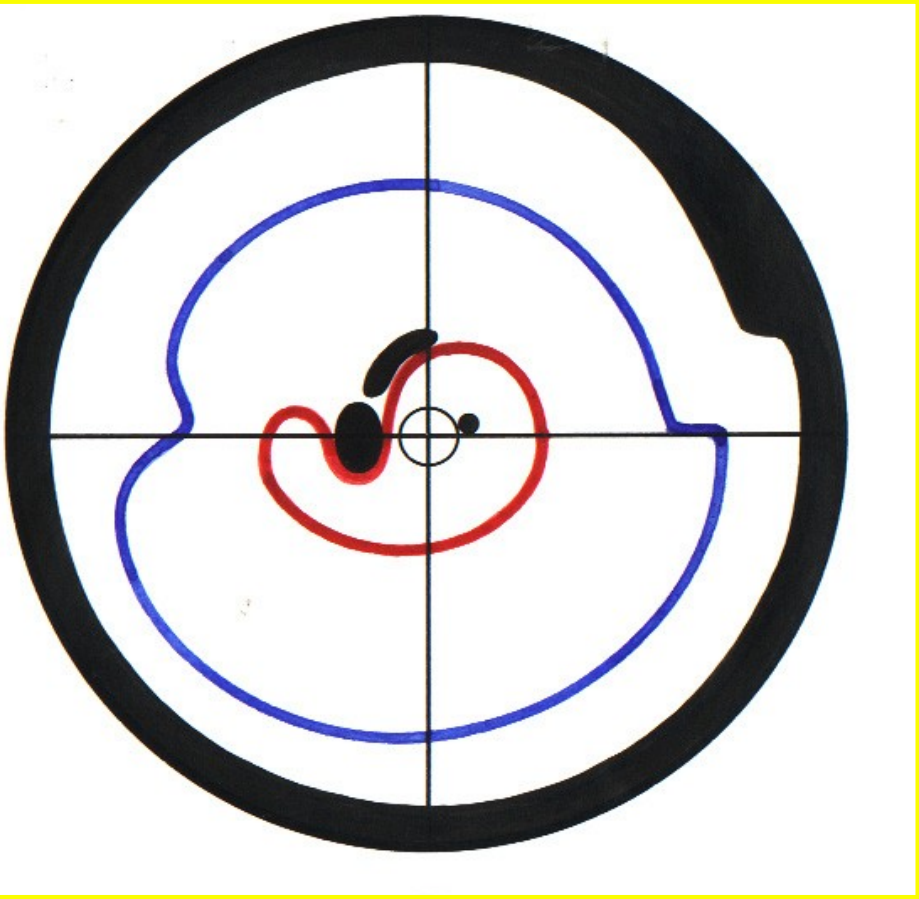

- Small arcuate scotomas
- Tend to elongate circumferentially

- Isolated paracentral scotomas
- Nasal (Roenne) step

Progression of visual field defects

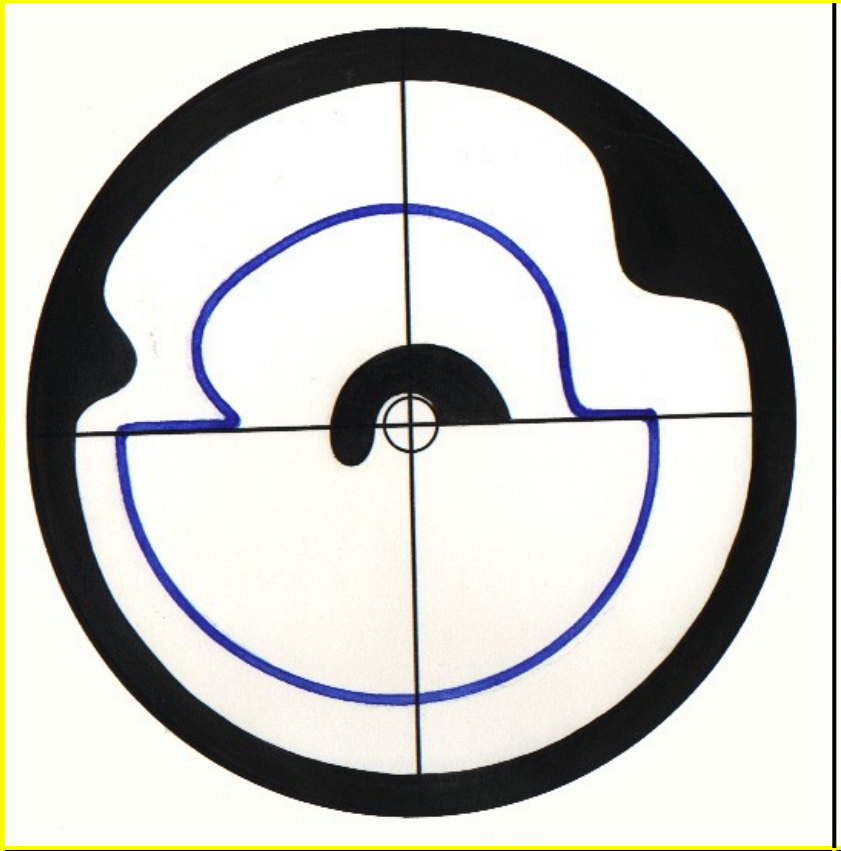



- Formation of arcuate defects
- Enlargement of nasal step
- Development of temporal wedge

- Peripheral breakthrough
- Appearance of fresh arcuate inferior defects

Advanced visual field defects



- Development of ring scotoma
- Residual central island

- Peripheral and central spread
- Residual temporal island

Drugs to treat glaucoma

1. Beta blockers
2. Sympathomimetics
3. Miotics
4. Prostaglandin analogues
5. Carbonic anhydrase inhibitors
   - Topical
   - Systemic

Laser trabeculoplasty

Indications

- Failed medical therapy
- Primary therapy in non-compliant patients

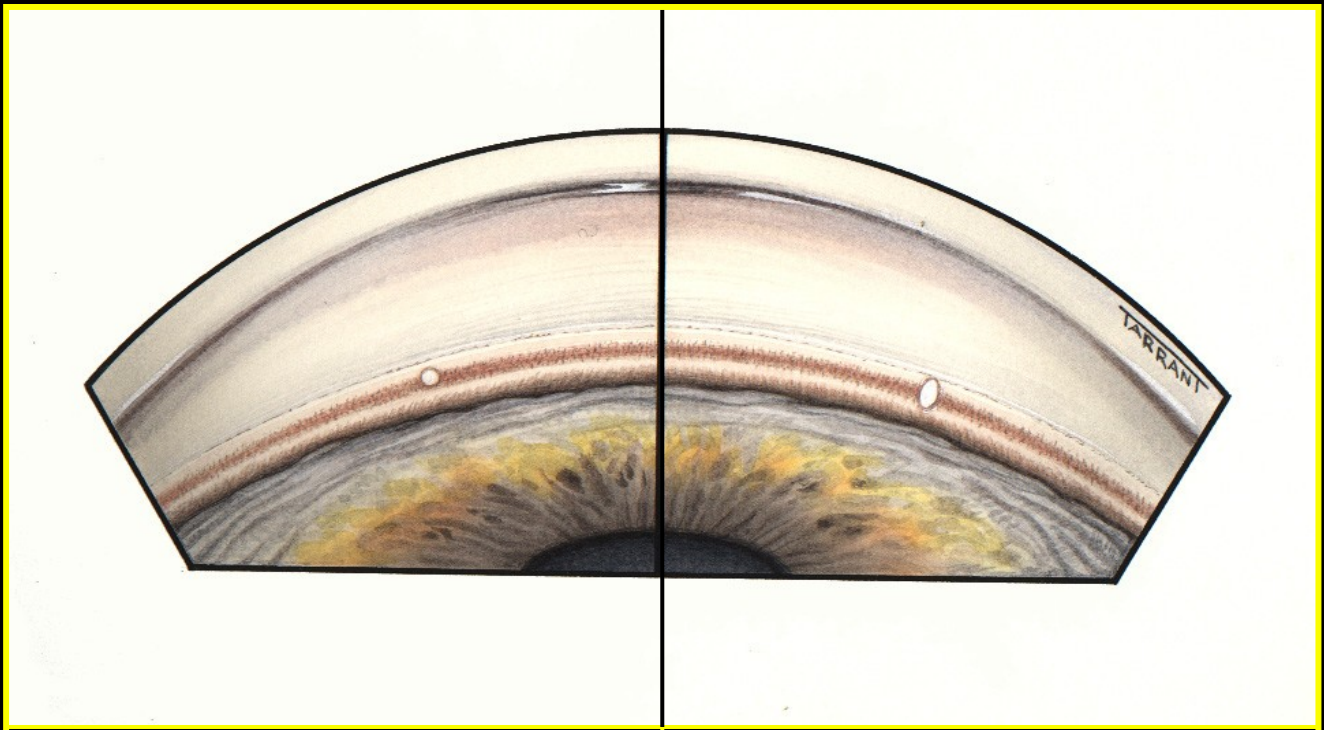

- Application of 50-100 burns to junction of pigmented and non-pigmented trabeculum
- Correct focus with round aiming beam

- Incorrect focus with oval aiming beam

Indications for Trabeculectomy

1. Failed medical therapy and laser trabeculoplasty

2. Lack of suitability for trabeculoplasty
   - Poor patient co-operation
   - Inability to adequately visualize trabeculum

3. As primary therapy in advanced disease

Technique (1)

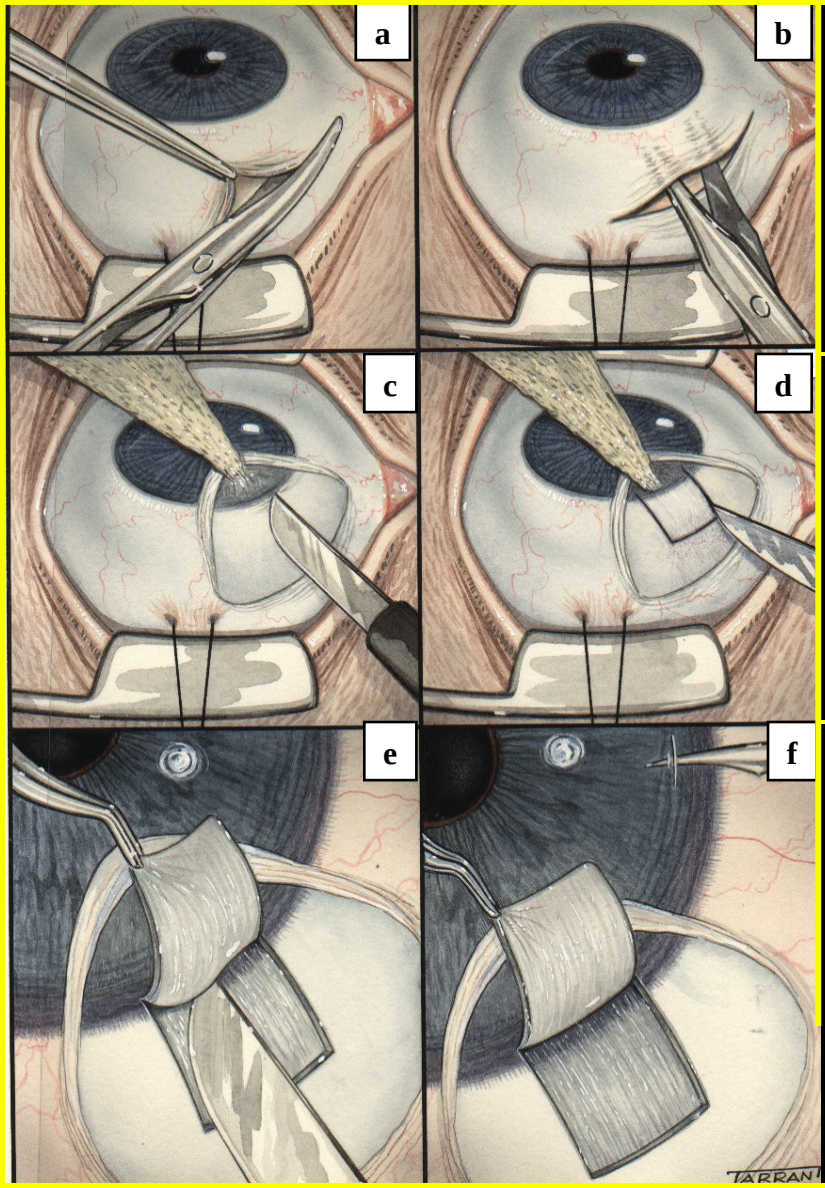

a. Conjunctival incision

b. Conjunctival undermining

c. Clearing of limbus

d. Outline of superficial flap

e. Dissection of superficial flap

f. Paracentesis

Technique (2)

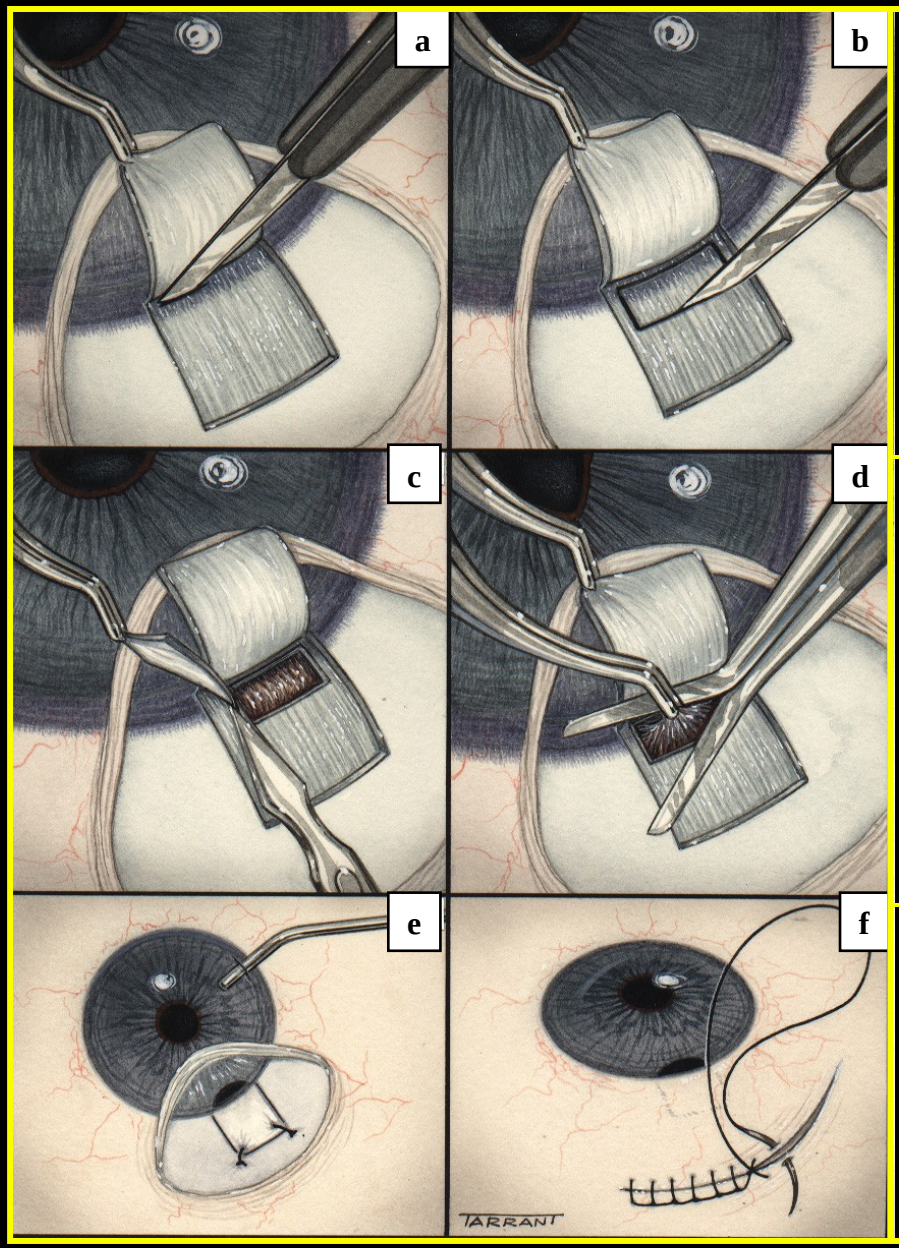

a. Cutting of deep block - anterior incision

b. Posterior incision

c. Excision of deep block

d. Peripheral iridectomy

e. Suturing of flap and reconstitution of anterior chamber

f. Suturing of conjunctiva

Filtration blebs

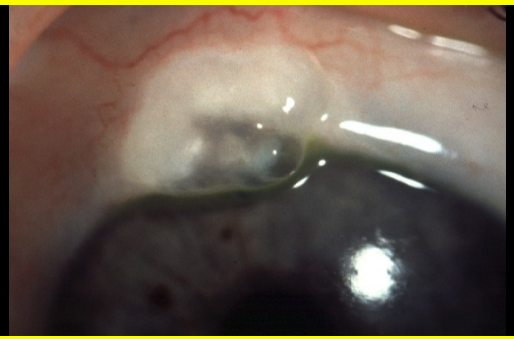

Type 1

- Thin and polycystic
- Good filtration

Type 2

- Flat, thin and diffuse
- Relatively avascular
- Microcysts present
- Good filtration

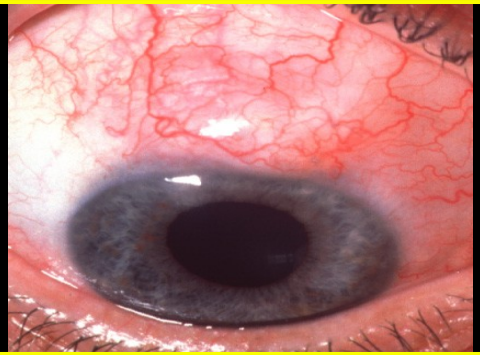

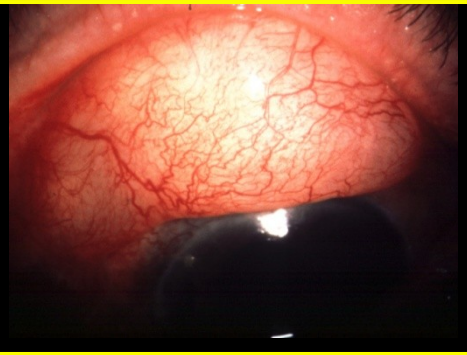

Type 3

- Flat
- Engorged surface vessels
- No microcysts
- No filtration

Encapsulated

- Localized, firm cyst
- Engorged surface vessels
- No filtration

Treatment Options for Failed Trabeculectomy

1. Digital massage
2. Laser suture lysis
3. Topical steroids
4. Subconjunctival injection of 5-FU
5. Re-operation
6. Re-commence medical therapy

Shallow anterior chamber

Cause	IOP	Bleb	Seidel test
Wound leak	low	poor	positive
Overfiltration	low	good	negative
Malignant glaucoma	high	poor	negative

Late bleb infection

Predispositions

- Thin-walled, cystic bleb
- Use of adjunctive antimetabolites
- Bleb trauma

Blebitis	Endophthalmitis
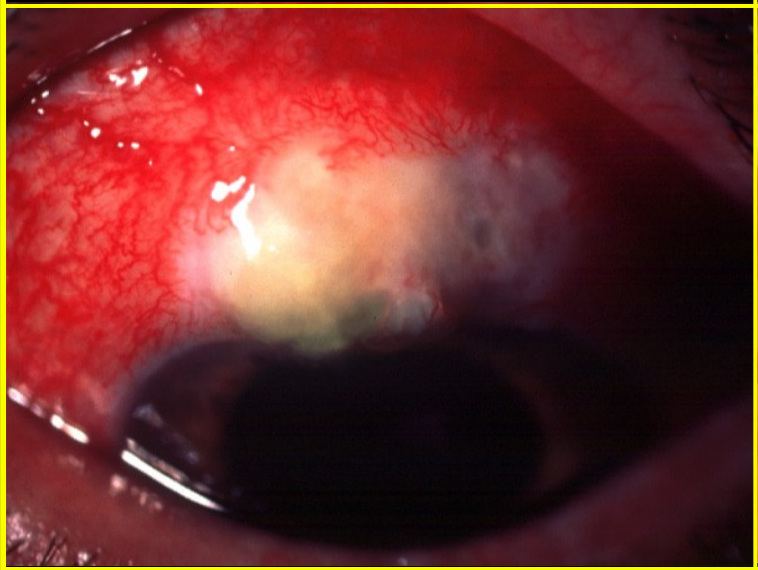	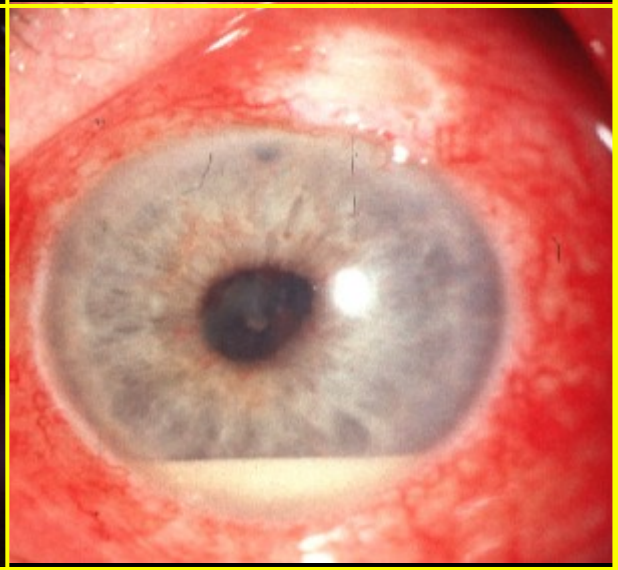
• Subacute onset • Milky bleb • No hypopyon • Good prognosis	• Acute onset • Hypopyon • Guarded prognosis